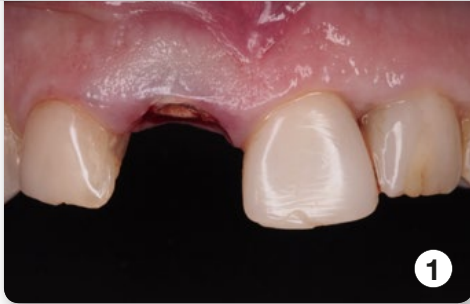


Case Study: Dr. Juanjo Iturralde –

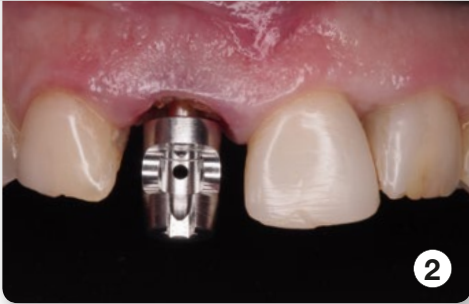Specialist Periodontics,
Implantology and Aesthetic dentistry
Director Clínica dental Iturralde
Tafalla (Navarra) / Spain



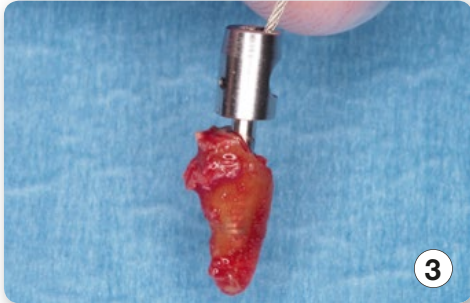Benex®
Pat.No. CH 696 458



Pre treatment

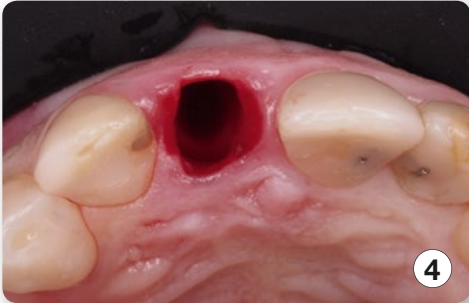

2



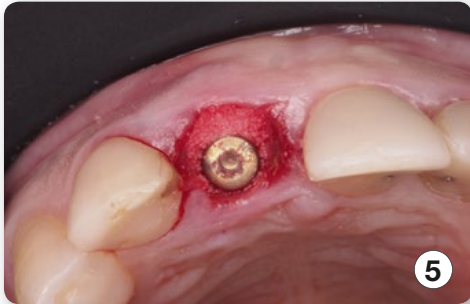3

Extracted root



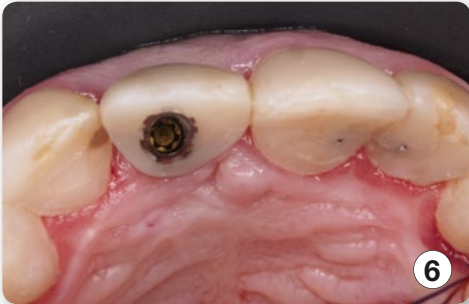4

View of the alveole



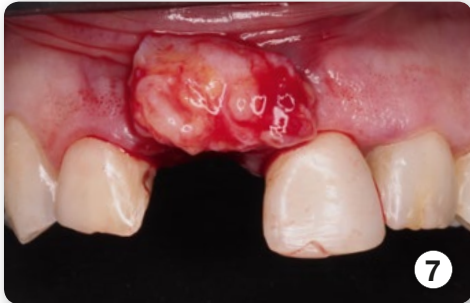5

3d positioning of the implant



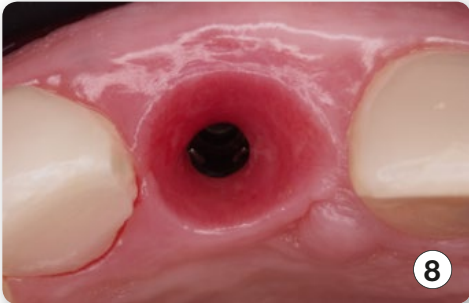
6

Temporary crown



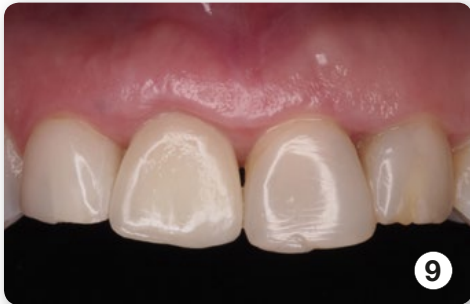7

Positioning of the transplant



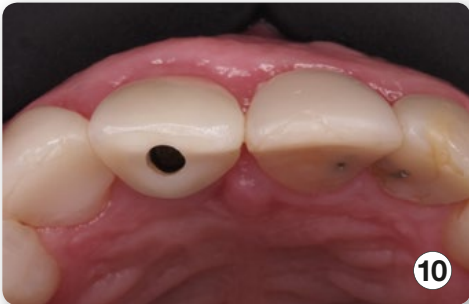8

Conservation of soft tissue



9

Final crown



10

View of the obtained soft tissue

